



Commissioning of the Lagos SICOT Education Centre

In this issue

| | |
|--|----|
| • Editorial: SICOT-J accepted in PubMed Central and DOAJ, by Hatem Said & Jacques Caton | 2 |
| • SICOT News: Commissioning of the Lagos SICOT Education Centre | 3 |
| • Scientific Debate: Management of dorsally displaced distal radius fractures: have we reached a consensus yet? | 4 |
| • Training Around the World: Female orthopaedic training in Saudi Arabia | 5 |
| • Fellowship News: 'SICOT meets SICOT' Fellowship: My experience after the fellowship in Erlangen, Germany | 6 |
| • Case of the Month: Chronic knee pain and swelling | 7 |
| • Update in Orthopaedics: Tranexamic acid optimal blood loss management in surface replacement arthroplasty | 8 |
| Comparison of simple arm sling and figure of eight clavicular bandage for midshaft clavicular fractures | 9 |
| • Exam Corner: Basic Science & Anatomy | 10 |
| • Congress News: 37 th SICOT Orthopaedic World Congress, Rome – Social Programme | 12 |



SICOT-J

accepted in PubMed Central and DOAJ

Hatem Said & Jacques Caton

SICOT Active Members & SICOT-J Editors-in-Chief – Assiut, Egypt & Caluire et Cuire, France

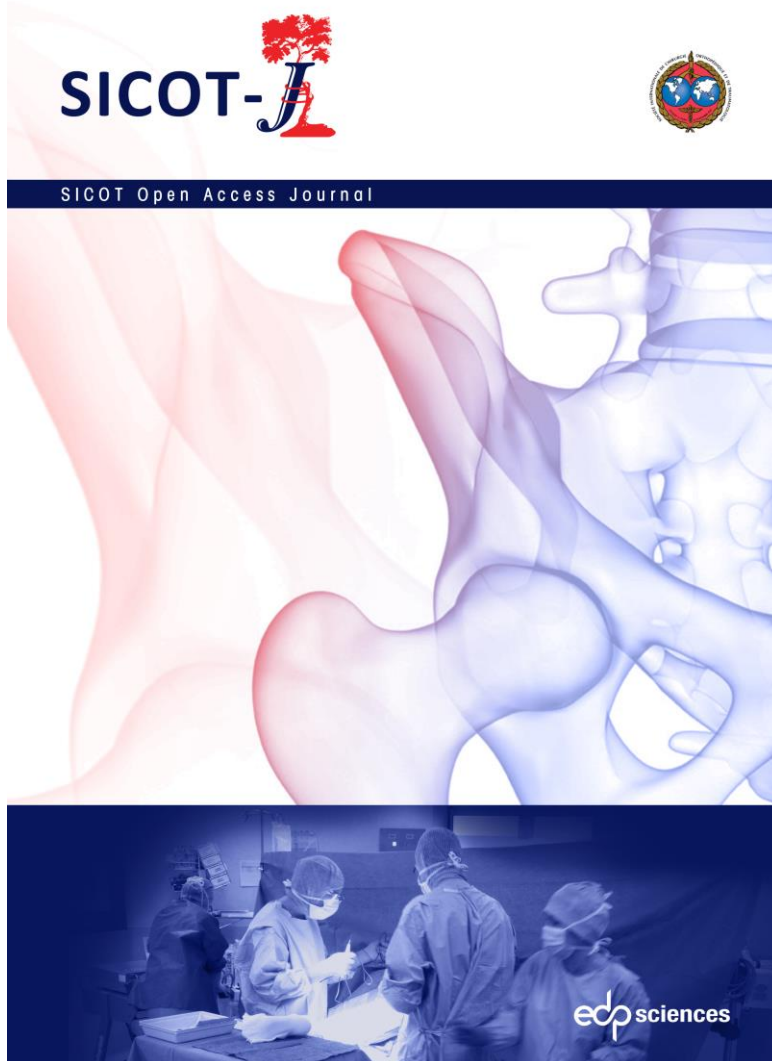The Editors and the publisher of SICOT-J are delighted to announce two important indexations of the journal: acceptance into PubMed Central and DOAJ (Directory of Open Access Journals).

SICOT-J has been added to the list of journals indexed by DOAJ, the service that lists open access journals committed to quality and peer reviewed open access content. Inclusion of a journal in DOAJ is a mandatory criterion for many funders, when researchers apply for a budget to finance “article processing charges”.

In addition, SICOT-J has been accepted for inclusion of its content by PubMed Central. This indexation will be effective as soon as the technical set-up is completed in the very near future, thereby leading to the indexation of all published articles since its launch in January 2015, as well as all forthcoming content.

The Board of the journal and EDP Sciences are very proud of the recognition of the exacting ethical and publishing standards applied by SICOT-J since the first published article. By this recognition, the Editors see encouragement to pursue their editorial policy and are also expecting that this will result in an increase of new article submissions.

SICOT-J would like to thank its Editorial Board, reviewers, and authors for their support to reach this important milestone.



Commissioning of the Lagos SICOT Education Centre



Wahab Yinusa

SICOT Active Member & SICOT National Delegate of Nigeria – Lagos, Nigeria

The Commissioning of the Lagos SICOT Education Centre took place on the second day of a three-day Arthroplasty Workshop on the hip and knee. The Workshop was well attended with about 50 orthopaedic surgeons and residents from different parts of Nigeria in attendance. Dr Maher Halawa, representing Prof Keith Luk, the SICOT President, participated and made useful contributions at the Workshop.

The Commissioning Ceremony of the centre which took place on 6 August 2015 in the Clinical Conference Hall of the National Orthopaedic Hospital was witnessed by about two hundred guests. Keynote messages were delivered by Dr Maher Halawa; Mr Linus Awute, Permanent Secretary of the Federal Ministry of Health; Dr O.O. Odunubi, Medical Director of the Hospital; and Dr Wahab Yinusa, SICOT National Delegate of Nigeria. Other highlights of the Ceremony included the unveiling of the plaque, the tour of the facilities in the centre, and the signing of the Memorandum of Understanding.

The event was widely publicised on the national television news and in the national newspapers.



From left to right: Prof Nwawolo (representative of the Provost of the College of Medicine), Dr Wahab Yinusa, Dr Maher Halawa, Mr Linus Awute, Dr O.O. Odunubi, Prof M.O. Ogirima (President of the Nigerian Orthopaedic Association), and Dr Nuhu Saliyu at the Commissioning Ceremony



Dr Halawa at the Education Centre



From left to right: Dr Halawa, Dr Yinusa, Mr Awute, Dr Odunubi, and Prof Ogirima unveiling the plaque

It is my pleasure to thank the Executive Committee of SICOT, Dr Maher Halawa who ably represented the SICOT President at the event, the Chairman of the SICOT Education Centres Committee, Dr Kandiah Raveendran, and all the SICOT members who attended the Ceremony.

More information about the SICOT Education Centres can be found at:

www.sicot.org/education-centres





Management of dorsally displaced distal radius fractures: have we reached a consensus yet?

Mohamed Sukeik

SICOT Associate Member & SICOT Newsletter Associate Editor – London, United Kingdom

Distal radius fractures are common. However, controversies remain in defining stable vs. unstable fractures, indications for non-operative vs. operative treatment and the ideal fixation method when an operation is deemed necessary.

The majority of distal radius fractures can be treated with closed reduction and plaster immobilisation which results in satisfactory outcomes in most cases [1]. However, multiple studies suggested that age, shortening, dorsal comminution, loss of radial inclination and AO type 3 fractures (A3, B3, C3) are associated with an increased risk of displacement [2]. In fact, a recent meta-analysis of 27 studies showed that dorsal comminution, female gender and age >60 years were particularly linked to unstable patterns. Such unstable fractures are often treated with either K-wires or a locking plate.

A number of studies attempted to evaluate predictors of outcomes in the operative group. For example, radiological predictors of high functional outcomes have been described as less than 2 mm of gap or step-off, restoration of the radius to within 2 mm of its normal length, and restoration of carpal alignment in McQueen's famous review article [3]. On the other hand, some studies highlighted that the ultimate aim is to achieve a pain-free, mobile wrist without functional limitation and hence relied on functional rather than radiological outcomes to assess the success of an operation [4, 5].

Over the last few years, there has been a tendency towards using locking plates as opposed to K-wires in the treatment of unstable dorsally displaced distal radius fractures as they improve radiological outcomes and as a result may be associated with improved functional outcomes [6, 7]. However, there remains a high major complication rate associated with using locking plates [8]. Therefore, a multicentred randomised controlled trial (RCT) including 18 centres and 461 patients from the United Kingdom was conducted recently to compare functional outcomes of K-wires vs. volar locking plates in the treatment of unstable dorsally displaced distal radius fractures [4]. In contrary to evidence from single centred RCTs favouring the use of locking plates [6, 7], results from this study did not show any statistically significant

difference in Patient Reported Outcome Measures (PROMs), Patient-Rated Wrist Evaluation (PRWE) and Disabilities of the Arm, Shoulder and Hand (DASH) scores regardless of age and intra-articular fracture involvement. On the other hand, cost analysis showed that K-wires are less expensive and are, therefore, more cost effective for these injuries. It is important to highlight though that there has been subjectivity in patient selection in this RCT as it was at the surgeon's discretion to include or exclude intra-articular fractures with no clear indication as to when it is still acceptable to do closed reduction and wiring as opposed to plating for those fractures. Additionally, follow-up remains short at one year but authors will continue following up and publishing the results of their findings accordingly.

A number of studies also compared operative and non-operative treatment in elderly patients and concluded that only minor objective functional differences were achieved in the operative group which did not result in an impact on subjective function and quality of life [9, 10]. As a result, elderly sedentary patients with low demands may still be treated with closed reduction and plaster immobilisation with good functional outcomes despite the presence of a residual deformity.

In summary, the majority of dorsally displaced distal radius fractures can be treated with closed reduction and plaster immobilisation. Extra-articular fractures within 3 cm of the radiocarpal joint and some intra-articular fractures which are deemed unstable but can be reduced closed are preferably treated by K-wiring. However, where closed reduction is not achievable or the fracture is intra-articular and highly comminuted, then a locking plate or other forms of treatment such as external fixators and bridging plates may be more appropriate. Elderly patients with low demands can be more tolerable to malunion with overall good functional outcomes when treated conservatively with closed reduction and plaster immobilisation.

References can be found at:

www.sicot.org/enewsletter-76-scientific-debate





Female orthopaedic training in Saudi Arabia

Sara Ghazi Qadi
Jeddah, Kingdom of Saudi Arabia



I am delighted to have this opportunity to write about my experience as a female trainee in an orthopaedic surgery programme.

Orthopaedic training in the Kingdom of Saudi Arabia (KSA) is a five-year programme divided into three years as a junior resident and two years as a senior resident. In the first year, we go through other specialties such as plastic and general surgery as well as ICU for 3 months each. After that, we spend the rest of our training rotating in different subspecialties of orthopaedic surgery.

The advantages of our programme is that we are able to practise in different centres and have the opportunity to work with many experts, thus providing us with good exposures in almost all subspecialties of orthopaedics such as trauma, spine, arthroplasty, paediatrics, oncology and sports.

As junior residents, we are the front line in emergency rooms and wards. We work as assistants in operating rooms and improve our skills performing surgeries under supervision.

Residents' promotion from year to year depends on the evaluation after each rotation and passing both the written and clinical examinations at the end of the year. We have two major examinations in addition to the yearly examination, one in the second or third year for promotion to senior level and another one at the end of our training.

We have four regions in the KSA and each region has its own centres and residents, all under the supervision of the

Saudi Commission for Health Specialties. In my region (Makkah al Mukarama), we have 12 certified centres for training between public and private hospitals, where from 79 residents, 15 of them are female!

As a female resident in my last year of training, I am very happy to have chosen orthopaedic surgery as a specialty and I have never regretted it even during the difficult days. This is simply because I loved and still love what we do for our patients and seeing how much what we do improves their functionality in life. For sure, sometimes it can become very difficult to balance between my heavy workload and being a mother, having to fulfil my family's needs. But at the end, with God's help and my family's support, I can do it.

In the last 5 years, the number of females in orthopaedic surgery increased to 35 in the KSA, 3 of which are consultants and the remaining are specialists and residents.

In the beginning, we did have some difficulties to be accepted by our colleagues and consultants as they expected that we would not be able to tolerate the work and be as good in orthopaedics as our male counterpart. Fortunately, this perception is gradually changing and we have proved ourselves in the field. They have found no difference between male and female surgeons in their work performance.

Finally, I would like to quote my colleague, Dr Amnah Baljoun, who once said: "As a female resident in my first year, I feel that I am always under the spotlight and I have to be extra good and extra prepared".



Awards

Don't miss the deadlines to apply for the Lester Lowe SICOT Awards (31 May), Marcela Uribe Zamudio Awards (30 April), SICOT-Kongress-Scholarship 2016 (30 May), and SICOT Travelling Scholarships (30 June) which are aimed at helping young surgeons attend the Congress.

More information at:
www.sicot.org/rome-awards





'SICOT meets SICOT' Fellowship: My experience after the fellowship in Erlangen, Germany

Pankaj Joshi

SICOT Associate Member – Aurangabad, India

I was very grateful to be selected for the 'SICOT meets SICOT' Fellowship at Alexander Friedrich University Hospital in Erlangen, Germany, in 2013.

I would like to share my thoughts and experiences with the SICOT Newsletter readers. Three years after the fellowship I feel that my skills, care and management of cases in trauma, orthopaedic and spine surgery have improved tremendously.

It was a refreshing experience undergoing this fellowship. It was like being back in residency training. When you are in practice, you may be too busy and unable to keep up-to-date with the latest orthopaedic knowledge. During this fellowship, I learned new techniques and skills in the management of hip, knee replacement and complex fracture cases.

During my fellowship, the exposure to various surgical cases was more than adequate. I was involved in a variety of cases from hip, knee and shoulder replacement to arthroscopic shoulder reconstructive surgery. I was also exposed to the navigation technique in scoliosis spine surgery.



Myself and Prof Raimund Forst in the operation theatre

Not only did I learn surgical techniques during the fellowship, but I was also involved in educational activities such as an orthopaedic forum where we discussed surgical cases, surgical planning with pros and cons of each surgical approach. The forum was attended by residents, orthopaedic surgeons as well as the senior orthopaedic surgeons. At

times, failed cases with complications were discussed openly and everyone was welcome to give opinions. We also discussed recent updates in the management of complex surgical cases.

During the orthopaedic forum, I was able to present cases and this improved my communication skills and piqued my interest in pursuing research of my own.

As I ponder and look back at my experience during the fellowship, I think, as orthopaedic surgeons, at some stage through our careers, we will encounter complications and failures. We may get anxious and apprehensive about sharing these cases with colleagues or seniors. In my 8 years of practice in orthopaedic and spine surgery, I have had my share of successes and failures. After undergoing training at international level, my confidence grew and I believe that we should share the complications and failures so we can learn from our mistakes.



Dr Fujak Albert, myself, and Dr Herde at the Paediatric Scoliosis Clinic

To my host, Prof R. Forst, Prof J. Forst and Dr Kress, it was a great opportunity for me and I am grateful for the teaching, particularly in techniques of muscle release in case of neuromuscular disorder and postoperative care.

Finally, I would like to thank the SICOT Fellowship Committee, Prof Jochen Eulert, Prof Raimund Forst, and Linda Ridefjord from the SICOT Head Office for planning an excellent fellowship schedule.

Chronic knee pain and swelling

Syah Bahari

SICOT Active Member and SICOT Newsletter Associate Editor – Seremban, Malaysia

A 20-year-old female presented with right knee pain and swelling over one month. The swelling has progressively worsened over that period. Patient denied any history of recent trauma or sport injuries. She also denied any febrile episode. She had no history of surgery to the right knee. She denies any weight loss or night pain.

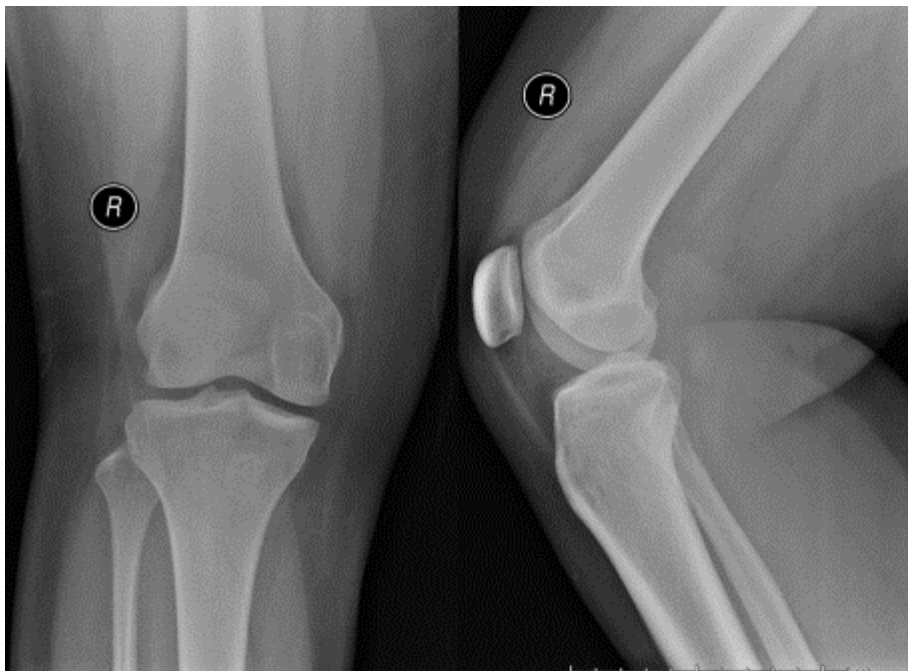
On examination, she was walking with an antalgic gait. Knee effusion was clinically detected. No focal bony

tenderness. Knee range of motion was slightly restricted. The knee was grossly stable. Radiograph of the right knee was performed.

Q. What are your thoughts on the findings of the knee radiograph?

Read more at:

www.sicot.org/enewsletter-77-signel-case



Makerere College of Health Sciences at Mulago Hospital/SICOT Fellowship

Every year, SICOT will offer two surgeons six-month fellowships to the Makerere University College of Health Sciences at Mulago Hospital, in Kampala (Uganda). The Fellowship will begin in July. No fellows will be received during the month of June.

The accommodation will be arranged by the Orthopaedic Department of the College of Health Sciences (Mulago Hospital). Travel and accommodation expenses will be

reimbursed by SICOT up to EUR 2,500 for a six-month period. Should the fellow go for a shorter duration, then the maximum amount will be reduced.

The subspecialties of the Mulago Hospital are Arthroplasty, Spine Surgery, Trauma and Paediatric Orthopaedics.

More information at:

www.sicot.org/makerere-fellowship



Tranexamic acid optimal blood loss management in surface replacement arthroplasty

A. Sassoon, D. Nam, R. Jackups, S.R. Johnson, R.M. Nunley, R.L. Barrack

DOI: 10.1302/0301-620X.98B2.36776 Published 5 February 2016

Comment by Mohamed Sukeik

SICOT Associate Member & SICOT Newsletter Associate Editor – London, United Kingdom

Abstract

Aims: This study investigated whether the use of tranexamic acid (TXA) decreased blood loss and transfusion related cost following surface replacement arthroplasty (SRA). *Methods:* A retrospective review of patients treated with TXA during a SRA, who did not receive autologous blood (TXA group) was performed. Two comparison groups were established; the first group comprised of patients who donated their own blood pre-operatively (auto group) and the second of patients who did not donate blood pre-operatively (control). *Outcomes included transfusions, post-operative haemoglobin (Hgb), complications, and length of post-operative stay. Results:* Between 2009 and 2013, 150 patients undergoing SRA were identified for inclusion: 51 in the auto, 49 in the control, and 50 in the TXA group. There were no differences in the pre-operative Hgb concentrations between groups. The mean post-operative Hgb was 11.3 g/dL (9.1 to 13.6) in the auto and TXA groups, and 10.6 g/dL (8.1 to 12.1) in the control group ($p = 0.001$). Accounting for cost of transfusions, administration of TXA, and length of stay, the cost per patient was \$1731, \$339, and \$185 for the auto, control and TXA groups, respectively. *Discussion:* TXA use demonstrated higher post-operative Hgb concentrations when compared with controls and decreased peri-operative costs.

Comment

Tranexamic acid is an anti-fibrinolytic agent commonly used in orthopaedic, cardiac, urological, obstetric and gynaecological surgery [1]. It works as a competitive inhibitor of plasminogen binding sites, thereby decreasing the conversion of plasminogen to plasmin which stabilises clot formation [1].

A number of Level 1 studies have confirmed the overall benefit of using TXA in reducing blood loss and transfusion rates with no significant associated complications in hip and knee arthroplasty surgery [1-3]. However, despite a few studies comparing the cost associated with TXA usage to allogeneic blood transfusion, not much has been reported in terms of a direct comparison between TXA and routine preoperative autologous blood transfusion [4, 5].

According to the authors of this study, TXA safely limited allogeneic transfusion in both the auto and control groups, maintained post-operative haemoglobin, and decreased direct and indirect transfusion related costs in surface replacement arthroplasty. Patients in the TXA group received 1 gram of TXA intravenously before incision and another 1 gram at the start of wound closure. History of deep vein thrombosis (DVT) and having undergone coronary artery stent placement within the previous year were exclusion criteria. The decision to perform an allogeneic transfusion was made by the treating surgeon and was dependent on a variety of clinical parameters. For example, symptomatic patients with orthostatic hypotension and light-headedness, and those with a postoperative Hgb of <8 g/dL or Hct <25% received a blood transfusion. If any of the patients had a history of coronary artery disease, or other cardiac risk factors, blood was transfused to ensure a Hgb of 10 g/dL or Hct of 30%. Intravenous heparin, as a single dose of 1000 units, was administered before hip dislocation. Drains were not routinely used. DVT prophylaxis was administered after assessing the risk of individual patients. The protocol for standard-risk anticoagulation therapy consisted of aspirin therapy (325 mg twice daily) for six weeks post-operatively and continued use of a mobile compression device for 23 hours a day for ten days post-operatively. High-risk patients were treated with warfarin therapy beginning the night before surgery and continued for four weeks post-operatively.

Strengths of this study include the homogeneity of the study population and comparing TXA to autologous blood transfusion and assessing allogeneic blood transfusion requirements.

Despite the retrospective nature of this study, it adds to the current literature further evidence to the benefit of using TXA in arthroplasty surgery. A well designed randomised controlled study would be ideal to confirm these study findings.

References are published at:

www.sicot.org/enewsletter-78-update-orthopaedics



Comparison of simple arm sling and figure of eight clavicular bandage for midshaft clavicular fractures. A randomised controlled study

A. Ersen, A.C. Atalar, F. Birisik et al. *Bone and Joint J* 2015;97-B:1562-5

Comment by Syah Bahari

SICOT Active Member and SICOT Newsletter Associate Editor – Seremban, Malaysia

Abstract

Only a few randomised, controlled studies have compared different non operative methods of treatment of midshaft fractures of the clavicle. In this prospective, randomised controlled study of 60 participants (mean age 31.6 years; 15 to 75) we compared the broad arm sling with the figure of eight bandage for the treatment of midshaft clavicle fractures. Our outcome measures were pain, Constant and American Shoulder and Elbow Surgeons scores and radiological union. The mean visual analogue scale (VAS) pain score on the first day after treatment was significantly higher (VAS 1 6.8; 4 to 9) in the figure of eight bandage group than the broad arm sling group (VAS 1 5.6; 3 to 8, $p = 0.034$). A mean shortening of 9 mm (3 to 17) was measured in the figure of eight bandage group, versus 7.5 mm (0 to 24) in the broad arm sling group ($p=0.30$). The application of the figure of eight bandage is more difficult than of the broad arm sling, and patients experience more pain during the first day when treated with this option. We suggest the broad arm sling is preferable because of the reduction of early pain and ease of application.

Comment

In December 2014, the SICOT e-Newsletter published a scientific debate article on the management of closed midshaft clavicle fractures. I was writing the article on behalf of the non-operative treatment options and I noted that there was a lack of recent evidences for non-operative treatment. When compared to open reduction and internal fixation treatment, the number of evidences published was more recent which showed improved functional outcome when compared to non-operative treatment. Furthermore, the recent randomised trials were comparing non-operative versus operative treatment

and none were comparing the various modalities of non-operative treatments.

Recently, this study was published on the above subject. I read it with interest and I found that the study conclusions on the use of non-operative treatment for closed, isolated midshaft clavicle fracture reassured me that the use of non-operative treatment is still applicable in our current practice.

I agree that the use of broad arm sling is more practical than the figure of 8 bandage. The study showed patients' tolerance to broad arm sling is better compared to the figure of 8 bandage. The rate of radiological union was within the expected norm. There was no case of non-union which was the main issue with non-operative treatment. However, the authors noted the small study population and high number of cases were undisplaced and minimally displaced which may explain the findings in their study.

The functional outcome at a mean follow-up of 8.3 months was satisfactory based on Constant and American Shoulder and Elbow scores. Their functional scores are comparable to other studies on clavicle fracture treated by operative treatment [1]. In my humble opinion, this study reaffirmed my conclusion that, in the right patient, non-operative treatment of closed midshaft clavicle fracture will yield similar results to operative treatment.

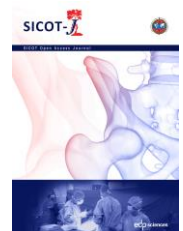
Reference:

Robinson CM, Goudie EB, Murray IR et al. Open reduction and plate fixation versus non operative treatment for displaced midshaft clavicular fractures: a multicenter, randomised controlled trial. *J Bone Joint Am* 2013 4;95(17):1576-84



Submit your article
to SICOT-J today!

More information at www.sicot-j.org



Basic Science & Anatomy

Prepared by Mohamed Sukeik

SICOT Associate Member & SICOT Newsletter Associate Editor – London, United Kingdom

Questions

- All of the below have an autosomal dominant inheritance pattern except:
 - Haemophilia
 - Osteochondromatosis
 - Ehlers Danlos syndrome
 - Kniest dysplasia
 - Metaphyseal epiphyseal dysplasia
- The inheritance pattern for all of the following is correct except:
 - Hypophosphatemic rickets: X-linked dominant
 - Hunters syndrome: X-linked recessive
 - McCune Albright syndrome: Sporadic mutation
 - Marfan syndrome: Autosomal recessive
 - Hypophosphatasia: Autosomal recessive
- The associated gene for all of the following is correct except:
 - Apert syndrome: FGF2R
 - McCune Albright syndrome: Gs alpha subunit of the receptor/adenylyl cyclase-coupling G proteins
 - Ehlers Danlos syndrome: COL 1A2 and COL 3A1
 - Synovial sarcoma: (X;19) (p11;q11)
 - Kniest dysplasia: COL 2A1
- Accumulation of sphingomyelin in reticuloendothelial system cells occurs in which of the following?
 - Hunter syndrome
 - Hurler syndrome
 - Morquio syndrome
 - Gaucher disease
 - Niemann-Pick disease
- Which of the following micro-organisms is associated with osteomyelitis in HIV patients?
 - Streptococcus viridans
 - Bacteroides species
 - Serratia marcescens
 - Eikenella species
 - Corynebacterium species
- Which of the following growth plate zones is affected in Osteopetrosis?
 - Reserve zone
 - Proliferative zone
 - Hypertrophic zone
 - Primary spongiosa
 - Secondary spongiosa
- Which of the following growth plate zones is affected in Osteogenesis imperfecta?
 - Reserve zone
 - Proliferative zone
 - Hypertrophic zone
 - Primary spongiosa zone
 - Secondary spongiosa zone
- Which of the following does not occur in osteoarthritis?
 - Increased water content
 - Increased chondroitin levels
 - Increased keratin sulfate levels
 - Articular cartilage degradation
 - Genetic predisposition
- Which of the following antibiotics inhibit cross-linking of polysaccharides in the cell wall by blocking transpeptidase enzyme?
 - B-lactam antibiotics
 - Aminoglycosides
 - Macrolides
 - Quinolones
 - Clindamycin
- Which of the following intervals is bordered by teres minor superiorly and contains the axillary nerve?
 - Medial triangular space
 - Triangular interval
 - Quadrangular space
 - Lateral triangular space
 - None of the above

11. Which of the following nerve injuries is associated with medial winging of the scapula?
 - a. Suprascapular nerve
 - b. Spinal accessory nerve
 - c. Long thoracic nerve
 - d. Dorsal scapular nerve
 - e. Axillary nerve
12. The clavicle fuses at the age of:
 - a. 5 weeks
 - b. 12 weeks
 - c. 1 year
 - d. 5 years
 - e. 25 years
13. The Thompson's approach utilises the interval between which of the following?
 - a. Extensor carpi radialis brevis and extensor carpi radialis longus
 - b. Extensor carpi radialis brevis and anconeus
 - c. Extensor and flexor carpi ulnaris
 - d. Extensor carpi radialis brevis and extensor digitorum
 - e. Brachioradialis and flexor carpi radialis
14. Matti's approach utilises the interval between which of the following?
 - a. First and second extensor compartments
 - b. First and third extensor compartments
 - c. Second and third extensor compartments
 - d. Second and fourth extensor compartments
 - e. Third and fourth extensor compartments
15. Which of the following is related to an abnormality in osteoclasts function?
 - a. Vitamin-D deficiency rickets
 - b. Vitamin-D dependent rickets
 - c. Hypophosphatasia
 - d. Paget's disease
 - e. Renal osteodystrophy
16. Which of the following is associated with reduced alkaline phosphatase levels?
 - a. Vitamin-D deficiency rickets
 - b. Vitamin-D dependent rickets
 - c. Hypophosphatasia
 - d. Paget's disease
 - e. Renal osteodystrophy
17. Which of the following disorders is an osteochondrosis affecting the ischiopubic region?
 - a. Van Neck's disease
 - b. Scheuermann's disease
 - c. Panner's disease
 - d. Kocher's disease
 - e. Thiemann's disease
18. Which of the following disorders is an osteochondrosis affecting the phalanges of the hand?
 - a. Van Neck's disease
 - b. Scheuermann's disease
 - c. Panner's disease
 - d. Kocher's disease
 - e. Thiemann's disease
19. Which of the following disorders is an osteochondrosis affecting the capitellum?
 - a. Van Neck's disease
 - b. Scheuermann's disease
 - c. Panner's disease
 - d. Kocher's disease
 - e. Thiemann's disease
20. Which of the following collagen types is usually seen in hypertrophic cartilage?
 - a. Type I
 - b. Type III
 - c. Type IV
 - d. Type X
 - e. Type XI

Answers can be found at:
www.sicot.org/enewsletter-79-exam-corner



37th SICOT Orthopaedic World Congress



8-10 September
2016

Rome, Italy

Social Programme

Opening Ceremony

Date Thursday, 8 September 2016
Time 17:45
Venue Rome Marriott Park Hotel & Convention Centre
Fee Free
Dress code Casual

Welcome Reception

Thursday, 8 September 2016
19:30
Rome Marriott Park Hotel & Convention Centre
EUR 22 (including 10% VAT)
Casual

Congress Dinner

Date Friday, 9 September 2016
Time 19:00
Venue Villa Miani
Fee EUR 88 (including 10% VAT)
Dress code Smart casual

The Congress Dinner will be held at the beautiful Villa Miani. Built high up on the slopes of Monte Mario in the early 1900s for the Miani Counts, this villa almost seems to brush the cupola of St. Peter's. Built in King Humbert

(Victorian) style, this wonderful home is immersed in the greenery of a beautifully kept garden, and offers a unique panorama overlooking the city of Rome. The villa is reached by a private drive of approximately 1km which cuts through its century old park. Today, Villa Miani is outside and yet inside Rome at the same time. It is located in a large, secluded park, away from traffic; yet, any point of the city below is easily accessible in a few minutes. In this way, Villa Miani preserves its exclusiveness. It has been a natural and aristocratic setting for many important events.

Closing Ceremony

Date Saturday, 10 September 2016
Time 12:45
Venue Rome Marriott Park Hotel & Convention Centre
Fee Free
Dress code Business attire or casual

Numerous awards will be handed out and the Congress will be officially closed during this Ceremony. There will also be a presentation about beautiful Cape Town, South Africa, the host city of the 2017 SICOT Congress.

To register for the Congress and for these events, please go to www.sicot.org/rome-registration



Editorial Department

Editorial Secretary: Hatem Said
Associate Editors: Syah Bahari & Mohamed Sukeik
Editorial Production: Linda Ridefjord
Editorial Board: Ahmed Abdel Azeem, Bassel El-Osta, Alexander McLawhorn

SICOT aisbl, Rue de la Loi 26 – b.13, 1040 Brussels, Belgium
Tel.: +32 2 648 68 23 | Fax: +32 2 649 86 01
E-mail: edsecr@sicot.org | Website: www.sicot.org

